	Body: MR Protocols		
	Reviewed:	Date: 4/22/26	J.Finizio
	Revised: Updated body protocols	Date: 4/22/26	Dr. Cai

Abdomen:

A 1: Pre- and post-contrast abdomen MRI (general, liver)

A 1P: Pre- and post-contrast abdomen MRI (MRCP/pancreas protocol)

A 1G: Pre- and post-contrast abdomen MRI (MRCP/gallbladder and leak protocol)

A 2: Pre- and post-contrast abdomen and pelvis MRI (renal protocol)

A 3: MR cholangiopancreatography (MRCP noncontrast protocol)

A 4: Abdomen MRI without contrast (adrenal protocol)

A 5: Pre- and post-contrast abdomen and pelvis MRI (Enterography protocol)

A 6: MRI superficial mass protocol

A6a: Pre-and post-contrast Chest (chest oncology protocol)

Pelvis:

P 1: Pre- and post-contrast pelvis MRI (gynecologic protocol, general pelvis)

P 2: Pre- and post-contrast pelvis MRI (rectal cancer protocol)

P 2P: Multiparametric prostate MRI (prostate protocol)

P 2K: Non-contrast pelvis MRI (prostate radiation planning protocol)

P 3: Pelvis MRI without contrast (appendicitis protocol)

P 4: Pre- and post-contrast pelvis MRI urethra, vagina, perineum

P 4B: Pre- and post-contrast multiparametric bladder

P 5: Pelvis MRI with *OR* without contrast (scrotal protocol)

P 6: Pre- and post-contrast pelvis MRI with MR angiography (uterine fibroid embolization protocol)

P7: Pelvis MRI without contrast (placenta protocol)

P8: Pelvis MRI with and without contrast (anal fistula protocol)

P9: Pelvis MRI defecography/pelvic floor

Cardiac:

C1: Cardiac MRI for cardiomyopathy

Whole body:

W1a: Li-Fraumeni initial

W1b: Li-Fraumeni followup

W2: Rb gene

W3: SDHx

General Notes

- The order of sequences is suggested to minimize table time
- T2 Sequences
 - When doing fat-saturation, T2FS (chemical shift) is preferred
 - T2 inversion recovery (STIR) and steady-state free precession (FISP, FIESTA) are generally not appropriate for body protocols and cannot be used post-contrast
- For longer sequences on patients who cannot breath-hold or inappropriate for respiratory-trigger, consider radial sequences (BLADE) or motion-correction acquisition if available
 - Prone positioning can also help

- If DIXON is used, please send only the "water" images (do not send the IP/OP/fat-only images)
- For IP/OP chemical shift imaging, do not use fat-sat
- For DWI, prefer b=50, 150, 800 with ADC maps (except prostate MRI)
- T1 FS VIBE preferred over T1 FS spin echo
- Coronal HASTE is the survey sequence with heavy T2 weighting. Suggested parameters: TR 1060/TE 116; BW 195; ST/gap of 6/0, 256x256, FOV 3040, phase R/L, NEX 1, R&L sat bands, interleaved.
- Suggested VIBE timing formula: Delay = $\frac{1}{2}$ injection time + arrival time – $\frac{1}{2}$ acquisition time + fudge factor (4 sec). Arrival time = time to peak signal in abdominal aorta.

For GE users

HASTE = SS-FSE

VIBE = LAVA

BLADE = PROPELLER

A 1: Pre- and post-contrast abdomen MRI (General, Liver)

Default protocol if abdominal MR if ordered without specific indication

Indications: abdomen pain, liver lesion workup

Sequences: patient supine (preferred) or prone if poor breath-holder.

- Coronal HASTE: hepatic dome to iliac crests.
- Axial 2D in- and out-of-phase
- Axial breath-hold T2 FSE
- Axial dynamic FS VIBE: pre-contrast, arterial, portal venous phases.
- Coronal FS VIBE portal venous phase
- Axial DWI and ADC
- Axial T2FS breath-hold
- Delayed post-Gd axial FS VIBE (5min)

Eovist variant:

Use if this is *first* MRI obtained for a patient with an incidental liver lesion, if requested by the prior report, or if requested by the referring provider

- Coronal HASTE: hepatic dome to iliac crests.
- Axial 2D in- and out-of-phase
- Axial dynamic FS VIBE: pre-contrast, arterial, portal venous phases.
- Coronal FS VIBE post-Gd
- Axial breath-hold T2 FSE
- Axial breath-hold T2FS
- Axial DWI and ADC
- Delayed post-Gd axial FS VIBE (at least 15min)

Liver iron quantification (optional request):

Obtain for exam indications that include one of the following phrases: Iron quantification, iron loading, hemosiderosis, hemochromatosis

Before administering contrast, choose a slice in the mid liver

Obtain T2* map

Continue rest of protocol

A 1P: Pre and post contrast abdomen MRI (Pancreas protocol with MRCP)

Indications: pancreatic lesion workup; malignant biliary stricture.

Sequences: patient supine (preferred) or prone if poor breath-holder.

- T2 coronal HASTE, full abdomen
- T2 breath-hold FSE thin-slice axial
 - No FS
 - Small FOV focusing on pancreas and bile ducts
- Axial 2D In/Out
- DWI/ADC
- 3D MRCP
- T1 axial FS VIBE non-con, arterial, venous
- T1 coronal FS VIBE venous phase
- T2 fat-sat, full abdomen, axial
- T1 axial FS VIBE delay

Comments:

- Thin slice spin-echo T2s should have TE >150 if not using fat-sat
- 3D SPACE - prefer FOV 330 if scan time is reasonable

**A 1G: Pre and post contrast abdomen MRI (Leak protocol with MRCP)
"EOVIST MRCP"**

Indications: bile leak

- Axial 2D In/Out
- T1 axial FS VIBE noncon
- T2 breath-hold FSE thin-slice axial, no FS, small FOV focusing on pancreas and bile ducts
- Coronal T2 (FS optional), small FOV focusing on pancreas and bile ducts

*inject Eovist contrast

- T2 axial HASTE, full abdomen
- T2 coronal HASTE, full abdomen
- T1 axial FS VIBE post-gad (will be a bit later than the usual venous phase, no arterial phase needed)
- DWI/ADC

*At least 15mins after contrast injection:

- T1 axial FS VIBE 15min delay
- T1 coronal FS VIBE 15min delay

Comments:

No 3D SPACE MRCP needed, biliary anatomy seen with Eovist T1 coronal delay

Thin slice spin-echo T2s should have TE >150 if not using fat-sat

A2: Pre- and post-contrast abdomen and pelvis MRI (renal protocol)

Indications: renal mass and hydronephrosis workup

Sequences: patient supine (preferred) or prone if poor breath-holder.

- T2 coronal HASTE, full abdomen
- T2 axial HASTE, full abdomen
- Axial 2D In/Out
- DWI/ADC
- T1 coronal FS VIBE non-con, arterial, 140s nephrographic
 - Optimize FOV for kidneys
 - Send subtractions for the arterial and nephrographic phases
- T1 axial FS VIBE full abdomen nephrographic phase
- T2 fat-sat coronal, full abdomen
 - This can be obtained while waiting for the 8min delay phase post-contrast
- T1 coronal FS VIBE delay (8min)
 - No need to send subtraction on this one

*Do not image the bladder/pelvis, no T2 “urogram” needed

Comments:

- For large patients, optimize FOV for the kidneys on the VIBE sequences, ok to exclude top of liver and body wall as long as the T2 HASTE sequences capture these regions
- Pre-exam hydration: 1000 cc of water *OR* 250 cc IV NS (preferred).

A 3: MR cholangiopancreatography (MRCP stones non-contrast)

Indications: assess for biliary obstructions

Sequences: patient supine (preferred); prone if poor breath-holder.

- T2 coronal HASTE, full abdomen
- T2 axial HASTE, full abdomen
- Axial 2D In/Out
- DWI/ADC
- T2 FSE thin-slice axial (no FS)
 - Small FOV focusing on pancreas to top of gallbladder
- 3D SPACE MRCP
- Coronal T2 (FS optional) Small FOV focusing on pancreas and bile ducts
- T1 axial fat sat VIBE non-con

Comments:

- Negative oral contrast agent can reduce signal from overlying stomach, taken a few minutes before exam (optional): 300 mL GastroMark, pineapple juice.
- Thin slice spin-echo T2s should have TE >150 if not using fat-sat
- 3D SPACE - prefer FOV 330 if scan time is reasonable

A 4: Abdomen MRI without contrast (adrenal protocol)

Indications: adrenal adenomas versus malignancy.

Sequences: patient supine.

- Coronal HASTE: hepatic dome to iliac crests.
- Axial 2-D in-phase
- Axial 2-D out-of-phase
- Subtraction images
 - In-phase minus out-phase (i.e.: high TE minus low TE)

Comments:

- Liver, renal, MRCP, pancreas protocols incorporate the above sequences already
 - If evaluating another solid organ lesion simultaneously, use the other protocol

A 5: Pre- and post-contrast abdomen and pelvis MRI (Enterography protocol)

Indications: Crohn's disease, bowel wall lesion characterization.

Sequences: patient prone (preferred).

- T2 coronal HASTE, large FOV
- T2 axial HASTE, centered between the lower pole of the kidneys and the iliac crest
- T2 fat-sat coronal, centered between the lower pole of the kidneys and the iliac crest
- T2 FS axial, pubic symphysis to below the anus[^]
- T2 FS coronal oblique parallel to sphincter, pubic symphysis to below the anus[^]
- DWI/ADC, centered between the lower pole of the kidneys and the iliac crest
- T1 FS VIBE coronal pre, 90s, 3min
 - Centered between the lower pole of the kidneys and the iliac crest
- Axial FS VIBE 90s abdomen
 - Centered between the lower pole of the kidneys and the iliac crest
- Axial FS VIBE whole pelvis[^]

Comments:

Do not acquire FISP/FIESTA to assess peristalsis

For large patients on the axials, do NOT split the upper and lower abdomen, center the FOV between the bottom of the kidneys and the iliac crest. Ok to cut off the hepatic dome.

For large patients on the coronals, ok to cut off the top of the abdomen and body wall

^These sequences are part of a perianal fistula screen, they do not replace the perianal fistula protocol.

Prone positioning will spread out bowel loops and decrease number of coronal slices needed for adequate coverage.

Oral contrast: three bottles of Volumen/ Breeza (450 mL x 3) oral contrast, 45 minutes prior to scan.

A 6: MRI with/without contrast superficial mass protocol

Indications: abdominal or chest wall lesion.

Sequences: *place fiducial over area of concern*; use smallest possible coil.

- Axial T2 HASTE large FOV

- Axial 2D IP/OP small FOV focusing on fiducial
- Axial T2 FS small FOV focusing on fiducial
- Coronal T2 FS small FOV focusing on fiducial
- Axial FS VIBE pre and post small FOV focusing on fiducial
- Coronal FS VIBE post small FOV focusing on fiducial

Comments:

- Flip phase/frequency if lesion is anterior to the heart at technologist discretion
- Suggested post-Gd delays: chest 25 sec, abdomen 30 sec, pelvis 35 sec. Better to wait too long than not long enough.

A 6a : Pre- and post-contrast Chest MR (oncology protocol)

Indications: Intrathoracic lesion or malignancy evaluation/follow-up

Sequences:

- Axial 2D in- and out-of-phase.
- Coronal 2D in- and out-of-phase.

- Axial T2 HASTE (Full Chest)
- Coronal HASTE (Full Chest)
- Axial DWI and ADC (Full Chest)
- Axial T2 FS (Use small FOV if focusing on particular lesion)
- Axial FS VIBE pre and post-contrast (Full chest)
- Axial FS VIBE post-contrast small FOV if focusing on particular lesion
- Coronal FS VIBE post-contrast (full chest)

P 1: Pre- and post-contrast pelvis MRI (gynecologic protocol, general pelvis protocol)

Indications: pelvic pain or other unspecific pelvis symptoms, gynecologic pelvic lesion evaluation

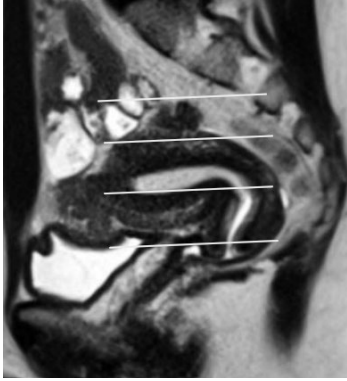
- Sequences: patient supine; scan from iliac wings or top of uterus to symphysis.

- Coronal HASTE large FOV
 - *Include up to the level of the renal pelvis*
- Sagittal breath-hold T2 FSE (pelvic sidewall to sidewall), small FOV
- Angled sequences with small FOV
 - Uterine long-axis T2 FSE (non-breath-hold)
 - Uterine short-axis T2 FSE (non-breath-hold)
 - Cervix short-axis T2 FSE (non-breath-hold)
 - If hysterectomy or male patient, obtain standard axial and coronal orientation with small FOV centered at the vaginal cuff or prostate region
- Axial T1 FLASH IP/OP
- Axial DWI and ADC.
- Axial T1 pre-Gd VIBE FS iliac crests to symphysis
- Sag T1 pre-Gd VIBE FS sidewall to sidewall
 - *If clinical indication "pelvic congestion": add coronal TWIST (8s after contrast, continuing for 2min), VIBE series are performed after 2mins*
- Axial post-Gd VIBE FS (30-40sec delay)
- Coronal post-Gd VIBE FS
- Sagittal post-Gd VIBE FS
 - No dynamics needed

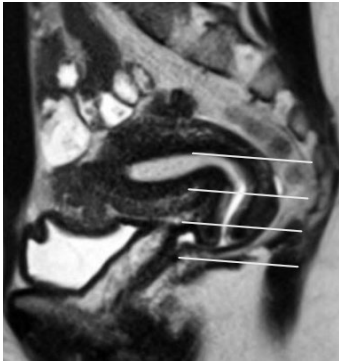
Comments:

- Patient Prep: Offer fleet Enema prior to scan (*Right before patient leaves home to come to exam*), rectal stool can cause exam to be non-diagnostic

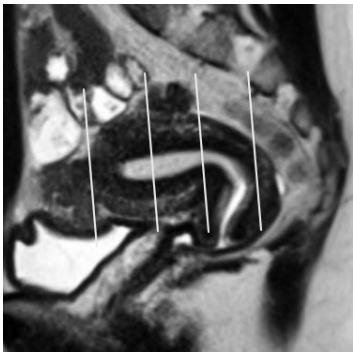
Uterus long axis



Cervix short axis



Uterus short axis



P2: Pre- and post-contrast pelvis MRI (rectal cancer protocol)

Indications: staging of known rectal cancer.

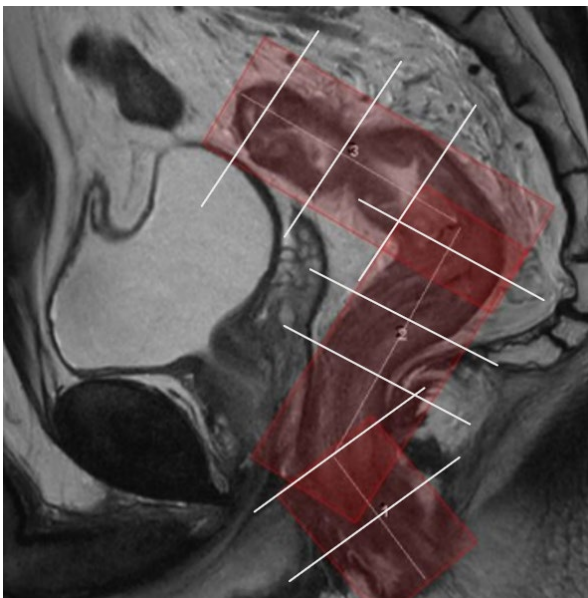
Sequences: patient supine, with saturation band across abdominal wall.

Scan from iliac crests to symphysis.

- Axial T2 HASTE large FOV
- 3 angled T2 FSE small FOV, non-breath-hold (See screen clip below)
 - *Include overlap of adjacent segments as shown in the screen capture*
- Sagittal axial T2 FSE small FOV, non-breath hold
- Axial DWI and ADC, whole pelvis
- Axial pre-Gd FS VIBE, whole pelvis
- Axial post-Gd FS VIBE, whole pelvis
- Coronal post-Gd FS VIBE, small FOV
- Sagittal post-Gd FS VIBE, small FOV

Comments:

- Patient Prep: Offer fleet Enema prior to scan (*Right before patient leaves home to come to exam*), rectal stool can cause exam to be non-diagnostic
- Empty bowel and bladder right before scan



P 2P: Multiparametric prostate MRI (prostate protocol)

Indications: Screening, known prostate cancer

Sequences: patient supine. Scan from iliac crests to symphysis only.

- Coronal T2 HASTE
- Axial T1 FSE with fat saturation
- Axial non-breath-hold T2 FSE (small FOV through prostate)
- Coronal non-breath-hold T2 FSE (small FOV)
- Sagittal non-breath-hold T2 FSE (small FOV)
- Axial DWI and ADC*
- Dynamic post-Gd axial VIBE through prostate (6 time points).
- Axial post-Gd FS VIBE with fat saturation
- Coronal post-Gd FS VIBE with fat saturation

Comments:

- Patient Prep: Offer fleet Enema prior to scan (*Right before patient leaves home to come to exam*), rectal stool can cause exam to be non-diagnostic
- T2 FSE specifications (if technically possible): ST 3mm no gap, FOV 12-20 cm, pixel size 0.7 mm or less (phase) and 0.4 mm or less (frequency).
- *DWI specifications (if technically possible): TE 90 ms or less, TR 3000 or more. ST 3 mm no gap. FOV 16-22 cm, pixel size 2.5 mm or less (phase and frequency).
 - B values: 50, 800, 1400. ADC.
 - Please send b2000 *calculated* B-value if available
 - Match FOV of the T2 axials with the ADC/DWI.
- Dynamic contrast enhancement (DCE): Dose: 0.1 mmol/kg standard contrast, injection rate 2-3 mL/sec. 3D VIBE preferred, fat saturation. TR <100 ms, TE <5 ms. ST 3 mm no gap, FOV to cover prostate gland and seminal vesicles, pixel size 2 x 2 mm or less. Temporal resolution: <7 sec preferred.
- Post contrast dynamic images: 6 time points should be sufficient.

P2K: Non-contrast pelvis MRI (prostate radiation planning protocol)

Indications: radiation therapy planning for prostate cancer

Per Dr. Whiton's protocol, SVH

Comments:

Scan to include top of seminal vesicles all the way down to include the base of the penis.

P 3: Pelvis MRI without contrast (appendicitis protocol)

Indications: assess for appendicitis *after* an inconclusive ultrasound, only for pediatric or pregnant patients

Sequences: patient supine.

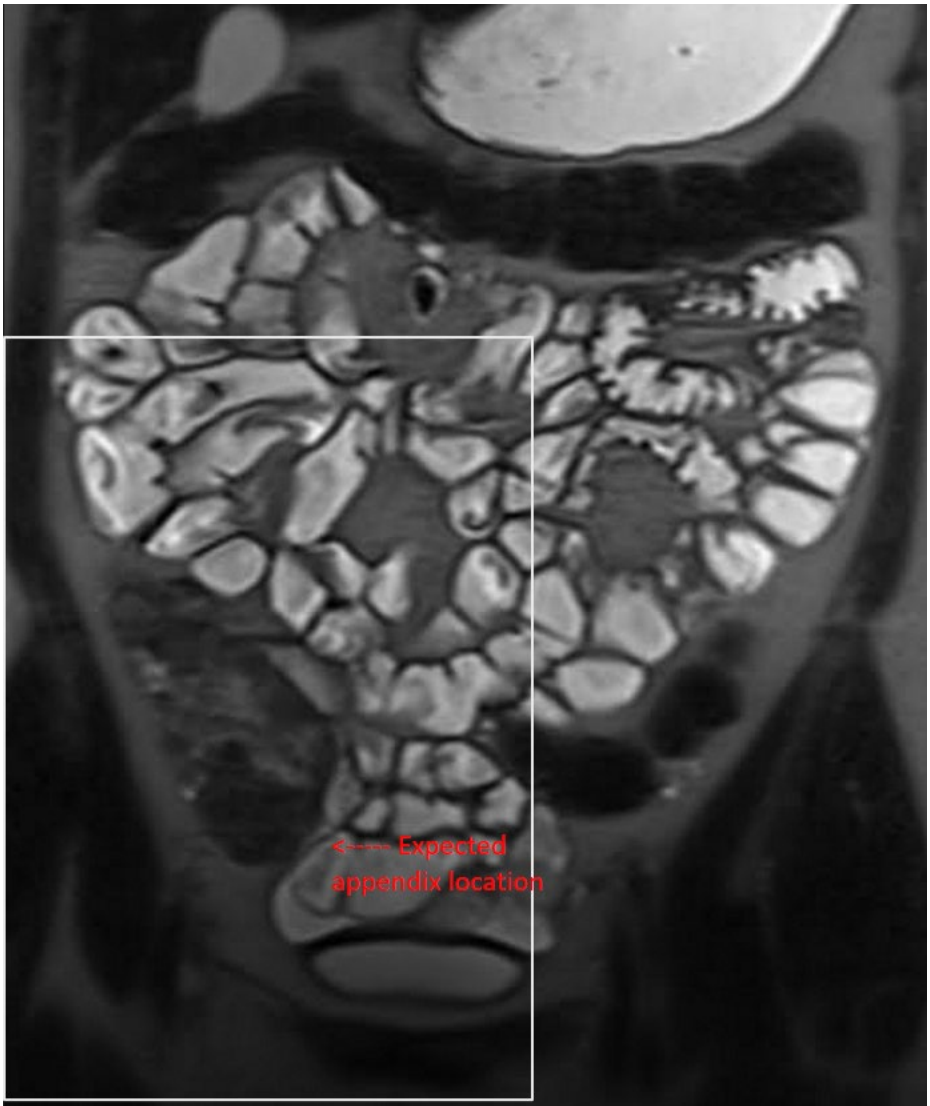
- Large FOV (top of kidneys to bottom of bladder): axial, sagittal T2 HASTE
- Large FOV (top of kidneys to bottom of bladder): coronal T2 *fat sat* HASTE
- Large FOV DWI and ADC

Small FOV centered in right lower quadrant and R pelvis (see screen shot below), message body radiologist if unsure

- Axial T2 HASTE thins
- Coronal T2 *fat sat* HASTE thins
- Axial FS VIBE non-con

Comments:

- Gadolinium is relatively contra-indicated in **ALL** pregnant patients
- Even though MRI has to date demonstrated no adverse effects to the fetus, it is relatively contra-indicated in the first trimester due to the amount of organogenesis in early pregnancy.
- Ok to use this protocol for ectopic pregnancy MRI - the small FOV series should be obtained over site of pain in the pelvis (not always in the RLQ)



P 4: Pre- and post-contrast pelvis MRI urethra, vagina, perineum
Indications: urethra, vagina, perineal lesions

Sequences: patient supine

- Coronal T2 HASTE: whole pelvis
- Axial T2 HASTE: whole pelvis
- Axial T2 TSE FS small FOV thins: top of symphysis to perineum
- Coronal T2 TSE FS small FOV thins: top of symphysis to perineum
- Sagittal 3D T2 small FOV ("MRCP"): top of symphysis to perineum
- Axial DWI and ADC whole pelvis
- Axial FLASH IP/OP whole pelvis
- Axial 3D FS GRE (VIBE) pre-Gd whole pelvis
- Axial FS VIBE post-Gd whole pelvis
- Axial FS VIBE post-Gd small FOV: top of symphysis to perineum
- Coronal FS VIBE post-Gd small FOV: top of symphysis to perineum
- Sagittal FS VIBE post-Gd small FOV: top of symphysis to perineum

Comments:

Patient Prep: Offer fleet Enema prior to scan (*Right before patient leaves home to come to exam*), rectal stool can cause exam to be non-diagnostic

P 4B: Pre- and post-contrast multiparametric bladder MRI
Indications: bladder lesion

Sequences: patient supine

***Bladder must be distended**

- Coronal T2 HASTE: whole pelvis
- Axial T2 HASTE: whole pelvis
- Axial T2 TSE FS *small FOV*: top of bladder to perineum
- Coronal T2 TSE FS *small FOV*: top of bladder to perineum
- Sagittal 3D T2 small FOV ("MRCP"): top of bladder to perineum
- Axial DWI and ADC *small FOV* on the bladder
- Axial FLASH IP/OP whole pelvis
- Axial 3D FS GRE (VIBE) pre-Gd whole pelvis
- Dynamic post-con axial VIBE (6 time points) *small FOV* through bladder
 - Same as the prostate protocol, but through the bladder
- Axial FS VIBE post-Gd whole pelvis
- Coronal FS VIBE post-Gd whole pelvis

Comments:

- Patient Prep: Offer fleet Enema prior to scan (*Right before patient leaves home to come to exam*), rectal stool can cause exam to be non-diagnostic

P 5: Pelvis MRI scrotal and penis protocol
Indications: scrotum, penis lesions and symptoms

Sequences: patient supine.

*penis is reflected superiorly, resting on the lower abdominal wall pointing up along midline

*scrotum and testes are resting on thighs, symmetrically placed

Use towels/tape if necessary

- Sagittal T2 HASTE: whole pelvis
- Axial T2 HASTE: whole pelvis
- Axial DWI/ADC whole pelvis
- Axial T2 TSE FS small FOV thins: top of penis to bottom of scrotum
- Sagittal T2 TSE FS small FOV thins: top of penis to bottom of scrotum
- Axial FLASH IP/OP whole pelvis
- Axial 3D FS GRE (VIBE) pre-Gd whole pelvis
- Axial FS VIBE post-Gd whole pelvis
- Axial FS VIBE post-Gd small FOV: top of penis to bottom of scrotum
- Sagittal FS VIBE post-Gd small FOV: top of penis to bottom of scrotum

P 6: Pre- and post-contrast pelvis MRI with MR angiography (uterine fibroid embolization protocol)

Indications: planning study for embolization.

Sequences: patient supine. Scan from top of uterus to symphysis

- Coronal T2 HASTE
- Sagittal breath-hold T2 FSE: center on uterus
- Uterine long axis breath-hold T2 FSE (see gynecologic protocol for screenshots)
- Uterine short axis breath-hold T2 FSE (see gynecologic protocol for screenshots)
- Axial DWI and ADC.
- Coronal MRA: pre-Gd, arterial phase *with MIP recons*, delayed venous phase.
- Post-Gd sagittal FS VIBE

Comments:

- Patient Prep: Offer fleet Enema prior to scan (*Right before patient leaves home to come to exam*), rectal stool can cause exam to be non-diagnostic

P 7: Pelvis MRI without contrast (placenta protocol)

Indications: placenta implantation abnormalities and previa

Sequences: patient supine. Scan from top of uterus to symphysis

For the angled axial short-axis sequences, see the gynecologic protocol section for a screenshot example

- Coronal T2 HASTE whole pelvis, include top of uterus
- Sagittal T2 HASTE whole pelvis, include top of uterus
- Axial DWI/ADC whole pelvis, from top of uterus
- Angled axial short-axis to uterus FISP/FIESTA from top of uterus to below bladder
- Sagittal FISP/FIESTA to include top of uterus and to below bladder
- Angled thin axial short-axis to uterus T2 HASTE *from bottom half of uterus to below bladder*
- Sagittal thin T2 HASTE small FOV *from bottom half of uterus to below bladder*
- Angled axial short-axis to uterus 3D FS GRE (VIBE) from top of uterus to below bladder

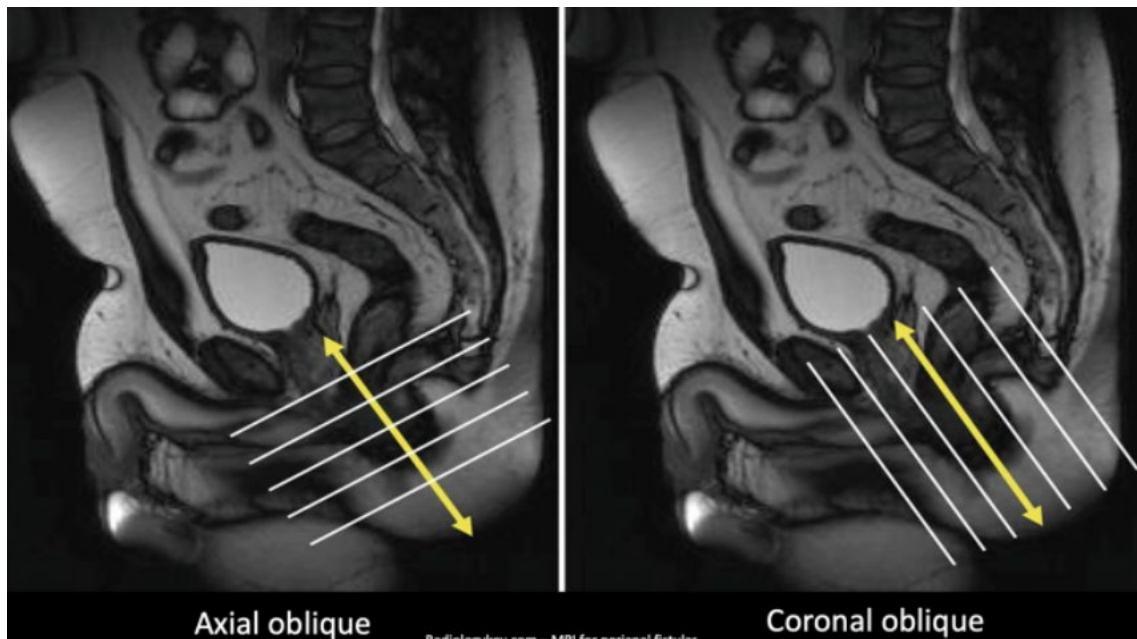
P 8: Pre- and post-contrast pelvis MRI (anal fistula protocol)

Indications: assess and characterize anal fistulas and abscesses.

Sequences: patient supine

See screenshot below for "axial oblique" and "coronal oblique"

- Sagittal T2 HASTE large FOV
- Coronal T2 HASTE large FOV
- Axial DWI/ADC, whole pelvis
- Axial oblique T2 TSE non-FS thins, small FOV
- Axial oblique T2 TSE FS thins, small FOV
- Coronal oblique T2 TSE FS thins, small FOV
- Axial oblique FS VIBE pre-Gd, small FOV
- Axial oblique FS VIBE post-Gd, small FOV
- Coronal oblique FS VIBE post-Gd, small FOV
- Axial FS VIBE, whole pelvis



P9: Pelvis MRI defecography/pelvic floor

Indications: pelvic floor, prolapse

Prep for defecography (not needed for pelvic floor):

No solid food 4h prior to exam, No IV required

Clear liquids ok up to 1h prior to exam

Warm ultrasound gel in 60cc slip-tip syringes

Have patient put on adult diaper

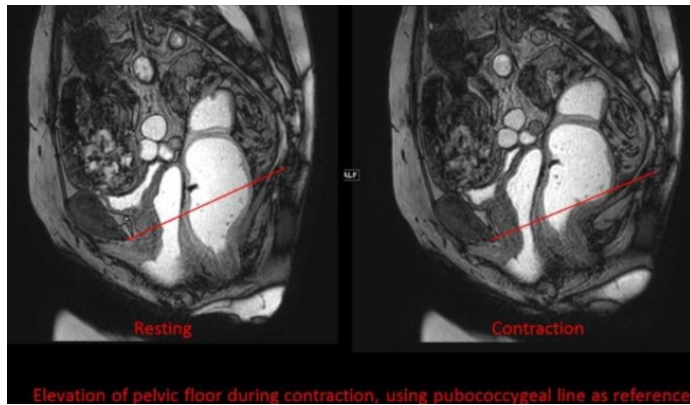
Administer ultrasound gel up to patient's tolerance using Foley (180cc in rectum, 60cc in vagina)

Do not push air (causes artifact)

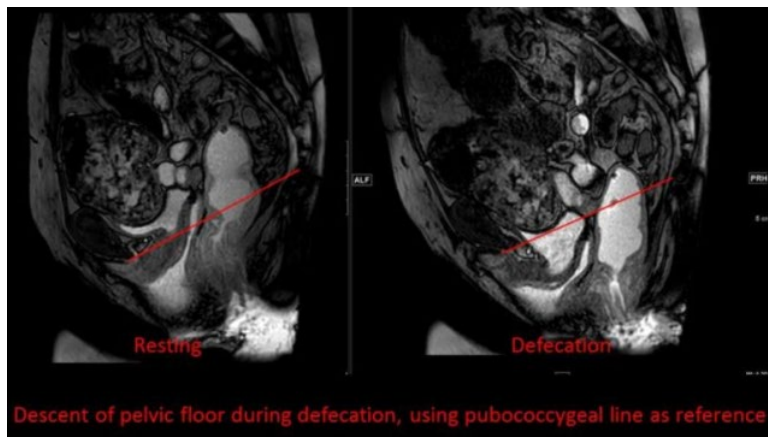
Sequences:

- T2 FSE breath-hold sagittal
- Acetabulum-to-acetabulum, top-of-sacrum to below perineum

- FISP CINE with contraction, use best midline sagittal slice
- 0.5s temporal resolution
- Sample instructions
 - "Perform a Kegel, hold.... Relax"
 - "Pretend you are stopping urination mid-stream, hold it.... Relax"
- Repeat as necessary with coaching, send best 3 attempts, discard other attempts



- FISP CINE with Valsalva (pelvic floor) or defecation (defecography), use best midline sagittal slice
 - 0.5s temporal resolution
 - Sample instructions
 - Pelvic floor: "Push, bear-down...relax"
 - Defecography: "Push, bear-down and defecate... relax"
 - Repeat as necessary with coaching, send best 3 attempts, discard other attempts



- T2 FSE coronal and axial (full pelvis)

Comment: FISP equivalents for non-Siemens vendors = FIESTA, FFE

C1: Cardiac MRI for cardiomyopathy

FLASH IP/OP: mid lung to bottom of pancreas

SSFP CINE 2C, 3C, 4C, LVOT with quantitative EF and volume analysis

Add RVOT, RV analysis for ACM (formerly called ARVD)

Short axis base to apex, 6 planes SSFP Cine

T2* map - short axis through mid heart, send raw images, greyscale map, and color map

*Inject contrast

Short axis dynamic perfusion

TI Scout

Short axis base to apex, 3 planes T2 TSE small FOV

DWI mid lung to bottom of pancreas

PSIR short axis, HLA, VLA

W1a: Li-Fraumeni initial

No solid food 4 hours prior to exam. No caffeine, chocolate, or milk. Other liquids are ok up to one hour prior to exam time.

Tech note: Shoulders to distal thighs. Neck imaging not required. Dedicated extremity imaging not performed though position arms close to body and include as much as possible in routine FOV. Send all coronal images to PACS stitched together, not individual scans

Perform with a brain w/wo

- Cor Stir Shoulders to Distal Thighs
- Cor DWI (b800) Shoulders to Distal Thighs
- Ax T2 Abdomen
- Brain pre
- Gadolinium injection

- Brain post
- Ax T1 fs post Shoulders to distal thighs
- Sag T1 fs post C/T/L spines

W1b: Li-Fraumeni followup (without contrast)

No solid food 4 hours prior to exam. No caffeine, chocolate, or milk. Other liquids are ok up to one hour prior to exam time.

Tech note: Shoulders to distal thighs. Neck imaging not required. Dedicated extremity imaging not performed though position arms close to body and include as much as possible in routine FOV. Send all coronal images to PACS stitched together, not individual scans

- Cor Stir Shoulders to distal thighs
- Cor DWI (b800) Shoulders to distal thighs
- Ax T2 Abdomen
- Ax T1 Shoulders to distal thighs
- Sag T2 C/T/L spines
- Sag Stir C/T/L spines

W2: Rb gene mutation

No solid food 4 hours prior to exam. No caffeine, chocolate, or milk. Other liquids are ok up to one hour prior to exam time.

*Tech note: Place hands palm facing inwards, flat against gluteus. Arms tightly against sides gives better chance to include both upper extremities in initial scan. Arms and hands may need to be imaged individually at end of exam if not evaluated well on initial whole body images. Send all coronal images to PACS stitched together, not individual scans

- Cor Stir Vertex to toes
- Cor T1 Vertex to toes

- Cor T2 haste Vertex to toes
- Ax T2 fs Chest, Abodmen, pelvis
- Ax T2 Chest to toes

If bilateral upper extremities not covered in above sequences, add:

- Cor Stir Right 2 stations shoulder to hand
- Cor Stir Left 2 stations shoulder to hand
- Cor t1 3D Right 2 station shoulder to hand
- Cor T1 3D Left 2 station shoulder to hand
- Ax T1 3D Right shoulder to hand
- Ax T1 3D Left shoulder to hand

W3: SDHx syndromes

No solid food 4 hours prior to exam. No caffeine, chocolate, or milk. Other liquids are ok up to one hour prior to exam time.

*Tech note: skull base to pelvis. Send all coronal images to PACS stitched together, not individual scans. Extremities not needed.

- Cor Stir skull base to symphysis pubis
- Cor T1 skull base to symphysis pubis
- Cor T2 haste Skull base to symphysis pubis
- Cor DWI b800 Skull base to symphysis pubis
- Ax T2 fs skull base to symphysis pubis
- Ax T2 skull base to symphysis pubis
- Ax T1 In/Out phase Abdomen